

HIGH ASTIGMATISM AND AMBLYOPIA

What are the options for improving the vision of this young patient?

BY PAVEL STODULKA, MD, PHD; BRETT MUELLER, DO, PHD; STEFANIE SCHMICKLER, MD; AND ABI TENEN, MBBS(HONS), FRANZCO

CASE PRESENTATION

A 31-year-old woman presents with a desire for improved vision in her amblyopic left eye. Upon examination, the patient's corrected distance visual acuity (CDVA) is 0.2 decimal OS with a refraction of $+1.75 -5.00 \times 10^\circ$. Her uncorrected near visual acuity (UNVA) is barely J13 OS and does not improve with her distance refraction. The right eye is slightly amblyopic, and her CDVA is 0.7 OD with a plano refraction.

She has worn glasses since childhood when her right eye was patched but does not like them. As a result, the patient currently wears spectacles only for driving. Mild horizontal nystagmus is evident and increases with sideways gaze. Scheimpflug corneal tomography of the left eye finds a central corneal thickness of $526 \mu\text{m}$, 4.90 D of regular astigmatism, and an anterior chamber depth of 2.8 mm (Figure 1). The endothelium is healthy, and endothelial cell density measures $2,800 \text{ cells}/\text{mm}^2$. No signs of dry eye disease and no intraocular pathology are found.

The patient is a social worker by trade and works in an office. She is aware of the severe amblyopia in her left eye and seeks any possible improvement. How would you proceed?

—Case prepared by Pavel Stodulka, MD, PhD



BRETT MUELLER, DO, PHD

A multifaceted approach is essential when evaluating someone with complex ocular conditions such as mixed astigmatism, amblyopia, and nystagmus for vision correction. First, a contact lens trial would be performed to determine whether the correction improves the

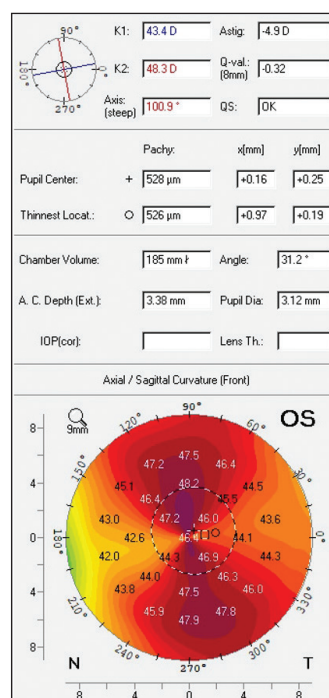


Figure 1. Preoperative Scheimpflug corneal topography.

vision in the patient's left eye without causing distortion. If the contact lens proves effective, further corrective measures could be contemplated.

In the United States, where I practice, there are several limitations on vision correction options for patients like this one. Implantation of an EVO ICL (STAAR Surgical) and laser-assisted lenticule extraction may not be performed on patients with mixed astigmatism. PRK, moreover, is considered unreliable for individuals who have mixed astigmatism. If there is no epithelial thinning or posterior float, LASIK could

be a viable option, provided it would leave a residual stromal bed that is greater than $300 \mu\text{m}$ and the percent tissue altered would be no more than 40%. It would be necessary to stabilize the patient's gaze to reduce her nystagmus significantly. If her eye movement remains pronounced across all gaze positions, unfortunately, she would not be a candidate for LASIK or any other form of surgical vision correction at this time. Custom lens replacement could be a viable alternative in the future, but I would recommend this option only when the patient is older.



STEFANIE SCHMICKLER, MD

The amblyopia and astigmatism are what disturb the patient the most. The former cannot be treated, but intraocular correction of her astigmatism might improve her visual acuity and reduce her nystagmus.

In my opinion, a toric phakic lens is not indicated, because the anterior chamber flattens with age. The anterior chamber depth is currently about 2.8 mm . Sooner or later, it will be too shallow for a phakic lens.

If intervening surgically, my preference would therefore be to perform a refractive lens exchange for a monofocal toric IOL such as the Tecnis Toric (Johnson & Johnson Vision). I would not make this recommendation

if the patient were not amblyopic, because the surgery induces presbyopia. In this case, the refractive target should be -0.50 D. Before proceeding to surgery, a contact lens trial would be performed to ensure that she can tolerate this amount of correction.

That said, given the unique situation and the patient's age, I would rather not perform surgery at present.



ABI TENEN, MBBS(HONS), FRANZCO

I would offer to perform LASIK on the patient's left eye. Despite her poor CDVA, the quality of vision in her left eye improves with refractive correction. Visual acuity is not the only measure of visual comfort and function, but amblyopic eyes are too often deemed unsuitable for refractive surgery. I would consider her a suitable candidate for surgery despite the limitations and ensure that she has reasonable expectations. For example, I would emphasize to her that refractive surgery cannot fix her amblyopia, only replace what glasses or contact lenses can do. She clearly feels that spectacle correction is beneficial, or she would not wear her glasses when driving.

The reasons the patient does not like her glasses are likely that she experiences image distortion, notices cosmetic asymmetry, and has nystagmus. I assume contact lenses have not been an option for her. Surgery should remove the discomfort associated with glasses.

Her history and test results show that she is a candidate for LASIK or an EVO ICL. A binocular cyclorefraction is required to determine the latent hyperopic component of both eyes. I would arrange for a contact lens trial in her left eye on a separate day, when

the pupil is no longer dilated, with what I call a *push to plus* refraction. For example, if the cycloplegic refraction is +2.75 -5.00 x 10° OS, I would test how much of the correction she can wear comfortably in trial frames and order a contact lens to match. A contact lens emulates the laser correction, which is important to test in patients with amblyopia and/or strabismus. Binocular alignment and single vision may decompensate in a contact lens as opposed to glasses; this information is important to ascertain before offering permanent correction with a laser.

I do not often correct more than 4.50 D of cylinder with laser ablation. I would therefore decrease the cylinder correction a little without expecting the reduction to make much, if any, difference in her vision. The laser correction would be +2.25 -4.50 x 10°. With this input, calculations of the expected postoperative keratometry readings with a 7-mm zone would be 43.40 and 48.30 D with a residual stromal thickness of 356 µm and a 120-µm flap (Schwind Amaris 1050RS, Schwind eye-tech solutions). It is worth noting that the cylinder on her corneal map is less than her subjective refraction, so treating the full 5.00 D might flip the axis, which could be an unfortunate outcome.

If there is significant latent hyperopia in the right eye, it may become manifest when the patient's accommodation relaxes after the LASIK procedure on the left eye. For this reason, my preoperative discussion with the patient would address the possibility of performing LASIK on the right eye in the future should she need it.

It would also be worth discussing ICL implantation as an option. If the refractive goal can be achieved with a less invasive procedure such as LASIK, however, that would be my preference. Given the patient's history, moreover, she may prefer to avoid the regular checkups that are necessary after ICL implantation.



WHAT I DID: PAVEL STODULKA, MD, PHD

Because the patient was a borderline candidate for both phakic lens implantation (anterior chamber depth, 2.8 mm) and LASIK (high astigmatism with a high amount of tissue ablation), surgery without corneal tissue ablation was elected. Corneal stromal lenticule rotation was performed to correct the high astigmatism in the patient's left eye with no tissue removal. A lenticule equal to one-half the preoperative amount of astigmatism was created with the VisuMax (Carl Zeiss Meditec; off-label use of laser) and rotated 90° inside a corneal pocket. (Scan the QR code to watch the procedure.)



One week after surgery, the eye had only 0.75 D of astigmatism on keratometry (Figure 2), and the patient's CDVA was 0.32 OS with a distance refraction of -4.00 D due to a myopic shift and an increase in spherical aberration, often associated with lenticule rotation. She noticed a slight improvement in her distance visual acuity and a significant improvement in her UNVA to J6 OS. Before surgery, the patient was unable to read even J13 uncorrected or with any correction in the left eye. At 6 months, her UNVA was J2 OS.

The patient was grateful for the slight improvement in her distance vision, but as an office worker, she was thrilled with the uncorrected reading vision in her left eye after surgery. The results and her level of satisfaction were stable at a 4-year follow-up visit.

This case suggests that even patients with severe amblyopia and high astigmatism can benefit from refractive

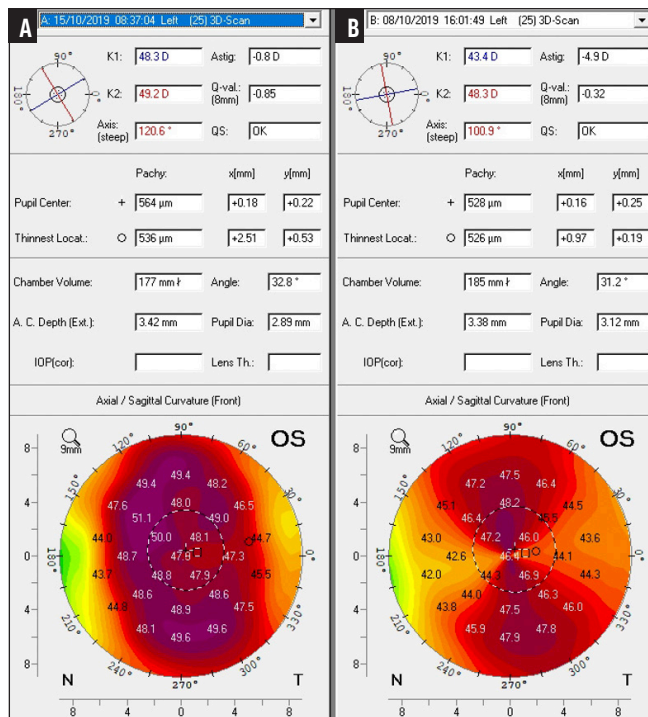


Figure 2. Corneal Scheimpflug topography preoperatively (A) and 1 week after surgery (B).

surgery and that corneal lenticule rotation is worth considering for these individuals because the procedure avoids the risks of intraocular surgery and high-volume corneal tissue removal. ■

GUEST SECTION EDITOR PAVEL STODULKA, MD, PHD

- Chief and CEO, Gemini Eye Clinics, Czech Republic
- Teacher, Third Faculty of Medicine, Charles University, Prague, Czech Republic
- Member, *CRST Global | Europe Edition* Editorial Advisory Board
- stodulka@lasik.cz
- Financial disclosure: None

BRETT MUELLER, DO, PHD

- Founder and Physician CEO, Mueller Vision, Dallas-Fort Worth metroplex, Texas
- Associate Academic Director, Refractive Surgery Alliance Fellowship Network
- Clinical Faculty and Assistant Clinical Professor, Rosenberg School of Optometry, San Antonio
- brett.mueller@muellervision.com; Instagram and X (formerly Twitter) @drbrettmueller
- Financial disclosure: Consultant (Alcon, Bausch + Lomb, Glaukos, Johnson & Johnson Vision, RxSight, STAAR Surgical, Tarsus Pharmaceuticals); Research support (Alcon)

STEFANIE SCHMICKLER, MD

- Augen-Zentrum-Nordwest, Ahaus, Germany
- st.schmickler@augen-zentrum-nordwest.de;
www.augen-zentrum-nordwest.de
- Financial disclosure: None

ABI TENEN, MBBS(HONS), FRANZCO

- Vision Eye Institute, Melbourne, Australia
- School of Primary Healthcare, Faculty of Medicine, Monash University, Melbourne, Australia
- School of Rural Medicine, Charles Sturt University, Bathurst, Australia
- abi.tenen@icloud.com
- Financial disclosure: None